

3D printed surgical guides for distal femoral osteotomy

T. Nagda¹, S. Parekh², and N. Belsure^{2*}

¹ Institute of Pediatric Orthopaedic Disorders (IPOD), Mumbai, India

² Imaginarium India Pvt. Ltd., Mumbai, India

* Corresponding author, email: nikhilbelsure@gmail.com

Abstract: Conventional surgical techniques have relied on 2D medical imaging for surgical planning and correction of a limb deformity. This results in certain deviations observed post-surgery from the conventional average values of limb and joint angles. Computer Aided Design (CAD) and manufacturing technologies, especially additive manufacturing, provide a solution through patient specific surgical guides. Patient specific surgical guides enable accurate cut of the bone and anatomically accurate corrections, mitigating the drawbacks of conventional surgery planning. This paper discusses the technology, materials, surgical planning technique and corroborates the accuracy of correction achieved with respect to the concerning pre-operative planning.

© 2021 N. Belsure; licensee Infinite Science Publishing

This is an Open Access article distributed under the terms of the Creative Commons Attribution License (<http://creativecommons.org/licenses/by/4.0>), which permits unrestricted use, distribution, and reproduction in any medium, provided the original work is properly cited.

I. Introduction

Osteotomy is a technique used to correct the deformity of the bones by cutting and realigning the deformed bones in anatomically correct position. Surgical planning is still predominantly done on two dimensional (2D) scanograms and images. 2D planning poses a challenge for correcting multiplanar and rotational deformities (1). Pre-bending of fixation plates also requires considerable trial and error in 2D planning.

Virtual surgical planning and 3D printed surgical guides propose to resolve the challenges associated with 2D planning. The process of the 3D virtual planning starts with Computer Tomography or Magnetic Resonance Imaging (CT/MRI) data acquisition, conversion of the CT/MRI data to a digital Computer Aided Design (CAD) model, and designing the custom guides.

II. Virtual surgery planning and guide design

Valgus deformity of the lower limb causes the knees to bow inward and giving a knock-kneed appearance. Distal femoral osteotomy is one of the corrective surgeries that can be performed for correcting the deformity. The CT scans of the patient are obtained making sure that the slice thickness and slice increments are less than 1mm. The CT scan is done only of the desired section of the lower extremities, eliminating the mid shaft regions to reduce radiation exposure. Weight bearing scanograms of the patient are sought in the anteroposterior view. Scanograms are important for ensuring the correct standing position for the virtual alignment of the 3D Model of the bone in the CAD software (Rhinoceros 3D). The DICOM data acquired through the CT Scan is segmented, and a virtual 3D model of the anatomy is generated. The 3D model of bones is obtained by segmentation (Materialise Mimics) of CT data. The position of the bones in three-dimensional data does not necessarily simulate the weight bearing. A

scanogram becomes imperative for the further alignment of the 3D model at accurate angles with respect to the scanogram (2). The virtual planning is based on the principles of deformity correction (3). The following were the steps to achieve the correction by determining the joint orientation angles as given in the Fig 1.

- Defining the anatomic and mechanical axes of the Femur, Tibia and hip, knee joint orientations.
- Measurement of joint orientation angles mLDFa (mechanical Lateral Distal Femoral Angle), aLDFa (anatomical Lateral Distal Femoral Angle), MPTA (Medial Proximal Tibial Angle), JLCA (Joint Line Convergence Angle), LPFA (Lateral Proximal Femoral Angle), MPFA (Medial Proximal Femoral Angle), Mechanical Axis Deviation (MAD).
- Axis planning for the deformed limbs by determining the proximal and distal mechanical or anatomic axis.
- Determining the accurate location of the CORA (Centre of Rotation Angulation) for osteotomy.
- Finding the Angulation Correction Axis and performing closed wedge osteotomy at the distal end of the femur.

The CORA can be located using two approaches, by using the intersection point between proximal and distal Mechanical axis (PMA & DMA) or using the intersection point between proximal and distal anatomic axis (PAA & DAA) in the anteroposterior view. The transverse Bisector Line (tBL) at the intersection of either proximal and distal mechanical or anatomic axis is the line of osteotomy and the Angulation Correction Axis (ACA) is located laterally (3). Closed wedge osteotomy is performed with the line of osteotomy at the level of CORA. The guide design for the patient specific surgical guides consisted of guides for the osteotomy and the plate fixation. A generic 9 hole Locking Compression Plate

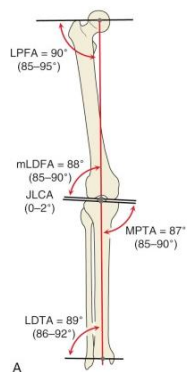


Figure 1: Joint Orientation angles by Dr. Dror Paley.

(LCP) is also imported into the CAD software along with the screws. The plate is aligned with the corrected anatomy and is bent for best fit. This provides the right plate orientation and screw length required for the surgery. A bone's surface is created in a CAD software which acts as a base model to design the guide. The cutting plane is defined at the tBT and cutting slots are provided keeping in mind the dimensions and the vibrating factors of the osteotome. The drill guide structures are created along the screw axis. K-wires are carefully inserted making sure it does not intersect with the screw holes and the cutting plane, as well, does not come in between while performing the osteotomy or drilling the screw holes. The K-wire guide structures are created. Overall thickness of the guide is provided to ensure stability and strength.

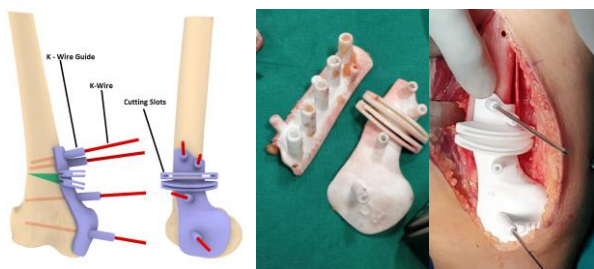

Figure 2: CAD model of the patient specific guide and the 3D Printed guide for a 15 year old patient with wedge marked.

Table 1: 3D Printing Specifications.

Particulars	Specifications
CT Segmentation software	Materialise Mimics
CAD Software	Rhinoceros 3D
3D Printing Process	Selective Laser Sintering (SLS)
Machine Make	3D Systems HiQ Sinterstation
Material State	Powder
Material Name	Duraform (Nylon Polyamide 12)
Material Colour	Natural White
Biocompatibility	USP Class VI Bio-Compatible
Sterilizable	Yes (ETO/ Gamma Ray / Autoclave)

III. Methods and material

The 3D Printing process chosen for manufacturing the guide is the Selective Laser Sintering (SLS) with certified biocompatible Polyamide-12 powder material also commonly known as Nylon.

IV. Results and discussion

The fitment of the guide on the distal medial femur was accurate. The correction achieved after the surgery matched with the values in the virtual surgery planning. Fig. 3 also shows the fluoroscope image of the correction in conjunction with the virtual planning done for a patient showcasing the accuracy of the 3D surgical plan and guides.

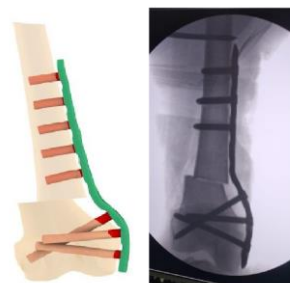

Figure 3: 3D virtual planning of the femur with the plate bending and fluoroscope image post-surgery.

The 3D virtual surgical planning greatly improved the surgical outcome by helping determine the correct location and angle of the wedge. These parameters were then used to design the patient specific guides to enable to surgeon to accurately determine the location on the bone and accurately cut the wedge. Furthermore, the placement guide also enabled the holding of the two fragments of the osteotomized bone together for plate fixation. The surgery time is also theoretically reduced in such surgeries (4).

V. Conclusions

3D virtual surgical planning is crucial in defining the extent of the deformity of the lower limb, especially multiplanar and rotational deformities. Patient specific 3D printed guides allow more accurate correction compared to conventional techniques, also reducing the surgery time. Usage of the guides also has the potential to reduce the radiation exposure and application in upper limb deformities as well. The authors routinely use the guides for lower limb corrective surgeries.

ACKNOWLEDGMENTS

The authors extend their gratitude to the IPOD, Mumbai team for their coordination and Imaginarium for planning and 3D printing the surgical guides. The authors state no funding was involved.

AUTHOR'S STATEMENT

The authors state no conflict of interest. Informed consent has been obtained from all individuals included in this study. The research related to human use complies with all the relevant national regulations and institutional policies, and has been approved by the authors' institutional review board or equivalent committee.

REFERENCES

- [1] M. Michielsen, *Corrective osteotomy of the distal radius malunions using three-dimensional computer simulation and patient-specific guides to achieve anatomic reduction.*, Eur Journal of Orthop Surg Traumatol 28, pp. 1531-1535, 2018.
- [2] J. Victor, *Virtual 3D planning and patient specific surgical guides for osteotomies around the knee*, The Bone and Joint Journal, 95-B:11, pp 153-138, 2013.
- [3] D. Paley, *Principles of Deformity Correction*, Springer, 2005, pp. 8-101.
- [4] J Shi, *Three dimensional patient-specific printed cutting guides for closing-wedge distal femoral osteotomy*. International Orthopaedics (SICOT) 43, pp. 619-624, 2019.